

pets, met with an untimely end, being stolen and killed for food by rapacious Burmese officials. By this the species appears to be capable of easy domestication, although said by some invariably to pine away and die after capture.

The horns of the species are, if large, kept by the natives for making handles for sickles; if small, they are of no value, and either thrown away or cut up and used as pegs. As to medicinal qualities, when a buffalo is bitten by a snake, the horn of the *Thamyn* ground to powder is mixed with a solution of the leaves of the "yekazoon" (*Ipomœa*, sp.), or wild convolvulus, and given internally as a dose. It is said to cure the bitten animal immediately. No other part of the beast appears to be used medicinally, and the above-mentioned nostrum is of no avail for the human race.

13. Notes on the Myology of *Iguana tuberculata*. By ST. GEORGE MIVART, F.L.S., Lecturer on Comparative Anatomy at St. Mary's Hospital.

The muscles of Saurian Reptiles (in which group I by no means include the *Crocodylia*) have not hitherto, as far as I know, been described in any detail, and have scarcely at all been figured. Many facts have certainly been recorded by Meckel\*; and Heusinger† has also published interesting notices (mainly referring, however, to those forms in which the limbs are rudimentary); but the greatest and most accurate record of saurian myology as yet accessible is that given in the second part of Professor Stannius's new edition of his 'Anatomy of the Vertebrata'‡.

It has been suggested to me that a series of notices, accompanied by woodcuts, of the main peculiarities presented by the myology of different oviparous vertebrates would be a not undesirable contribution to comparative anatomy; and I have now the honour of laying before the Zoological Society the results of my dissection of a fine specimen of *Iguana tuberculata*, for the opportunity of making which I am indebted to the rich stores of the collection of the Royal College of Surgeons, and to the kindness of my friend Mr. W. H. Flower.

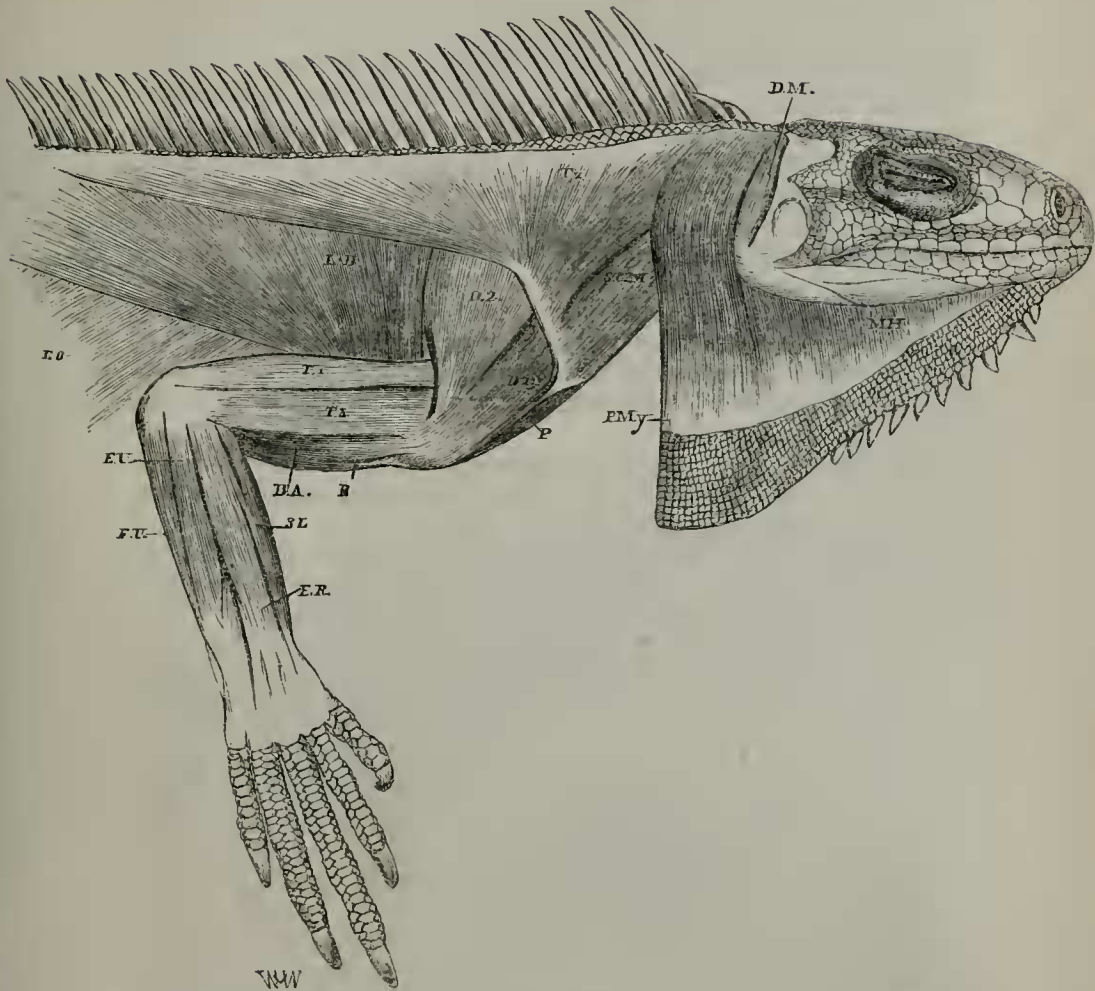
A correct determination of Saurian muscles, especially those of the posterior extremity, is not to be hoped for in a first attempt. I have therefore thought it well to begin with the Iguana, because it is a common species, readily procurable, on which account my errors and misinterpretations will be the more easily rectified.

\* *Traité général d'Anatomie comparée*, par J. F. Meckel: traduit de l'allemand par MM. Riester et Alph. Sanson (Paris, 1829): tome v. 1<sup>re</sup> partie, et tome viii.

† In *Zeitschrift für organ. Physik*. Bd. iii. Hft. 5. p. 481.

‡ *Handbuch der Zootomie*, von Siebold und Stannius. Zweiter Theil. Die Wirbelthiere. Zweite Auflage. Zweites Buch. Die Amphibien (Berlin, 1856), pp. 100, 117, 122, 126, 133.

Fig. 1.



Superficial muscles of outer side of thorax and arm, and of extensor surface of forearm,—the gular pouch being cut to show more of the sterno-cleido-mastoid.

- B.* Biceps. *B. A.* Brachialis anticus. *D. 1.* First part of deltoid. *D. 2.* Second part of deltoid. *D. M.* Depressor mandibulae. *E. O.* External oblique. *E. R.* Extensor carpi radialis. *E. U.* Extensor carpi ulnaris. *F. U.* Flexor carpi ulnaris. *L. D.* Latissimus dorsi. *M. H.* Mylo-hyoid. *P.* Pectoralis major. *P. My.* Platysma myoides. *S. C. M.* Sterno-cleido-mastoid. *S. L.* Spinator longus. *Tz.* Trapezius.

#### MUSCLES OF THE HEAD AND TRUNK.

*Mylo-hyoid* (fig. 1, *M. H.*). This is a thin muscular layer, arising from the outside of the posterior part of the mandible and from the inferior margin of the middle and more anterior portion of the bone. It does not, however, extend to its anterior end. Descending inside the skin of the gular pouch its fibres gradually become lost.

Fibres similarly disposed below, but ending above in the fascia

covering the trapezius, constitute a more posterior layer of superficial fibres having no connexion with the mandible; these may perhaps represent the *platysma myoides* (fig. 1, *P. My.*).

On removing the *mylo-hyoid* a muscle becomes visible which is of rather large size, and descends from the middle of the lower border of the inner surface of the mandible to the cornu of the os hyoides. This is the *cerato-mandibular* (fig. 2, *C. M.*).

The *depressor mandibulæ*, which may perhaps represent the digastric (figs. 1, 2 & 2A, *D. M.*), arises from the posterior margin of the parietal process. Descending, it is inserted into the extreme posterior end of the mandible.

The *temporal* muscle is very thick and large, and fills the temporal fossa. It arises from the outside of the parietal process and from the front surface of the os quadratum\*. It is inserted into the coronoid process of the mandible, and into the upper border of the bone behind that process.

*Internal pterygoid.* This large, thick muscle takes origin from the inner side of the pterygoid, and is inserted into the inside and posterior extremity of the mandible.

The *external pterygoid* arises outside the pterygoid, and is inserted into the inner surface of the mandible rather in front of the insertion of the internal pterygoid and behind the coronoid process.

*Trapezius* (figs. 1 & 2, *Tz.*). This muscle, as Meckel observes†, is very extensive. It lies beneath the *platysma myoides*, but superficial to the *levator claviculæ*; and the lowest part of its insertion overlaps that of the *omo-hyoid* (fig. 2, *Tz.*, *O. H.*). It forms a very delicate muscular layer, especially above, but becomes thicker towards its insertion. It arises, by aponeurosis, from the middle line of the back, from the last cervical to the fifth dorsal vertebra, and more anteriorly from the superficial fascia of the neck, and also from the margin of the parietal process, towards which part it is intimately united to the *sterno-cleido-mastoid*. The fibres converge, and are inserted into about the upper half of the clavicle between the *deltoid* and the insertions of the *levator claviculæ*, *omo-hyoid*, and *sterno-cleido-mastoid*. The most anterior and posterior fibres antagonize each other.

The *rhomboid* is wanting, unless it be represented by some part of the muscle described as the *serratus magnus*.

*Latissimus dorsi* (figs. 1 & 9, *L. D.*). This is a large muscle, and arises from the spines of the dorsal vertebræ from the first to the ninth, and from the last three cervical spines. Its fibres, converging, end in a strong tendon, which is inserted into the outer side of the summit of the humerus below, passing rather in front of, the insertion of the *infraspinatus*, covered moreover by the third head of the *triceps*. The tendon of the *latissimus dorsi* gives off another small tendon from its inferior margin (fig. 9, *t.*), which joins the *triceps* just where the two long heads of that muscle unite together.

\* The part arising from the os quadratum and columella is considered by Stannius to be the *masseter*.

† *Loc. cit.* p. 311.

*Longissimus dorsi.* This is small and very indistinctly separable from the sacro-lumbalis. It partly arises from the posterior end of the crest of the ilium; partly it is the anterior continuation of the dorsal series of caudal muscular cones, or rather to the halves of those cones. Passing forwards it is inserted into, and takes fresh origin from, the spines and adjacent parts of the vertebræ.

The *sacro-lumbalis*, though wide, is very thin, except at its posterior end, and it is very imperfectly separable from the last. It arises from the crest of the ilium, and appears to be partly continuous with the supracaudal muscular mass. It is inserted, in an indistinct manner (by tendinous intervals which become more marked from behind forwards), into the ribs, including the cervical ones, as it passes insensibly into the cervicalis ascendens.

*Complexus major* (figs. 2 & 2A, *C. Ma.*). This is an elongated muscle arising by tendinous fibres from the spines of the first and

Fig. 2.

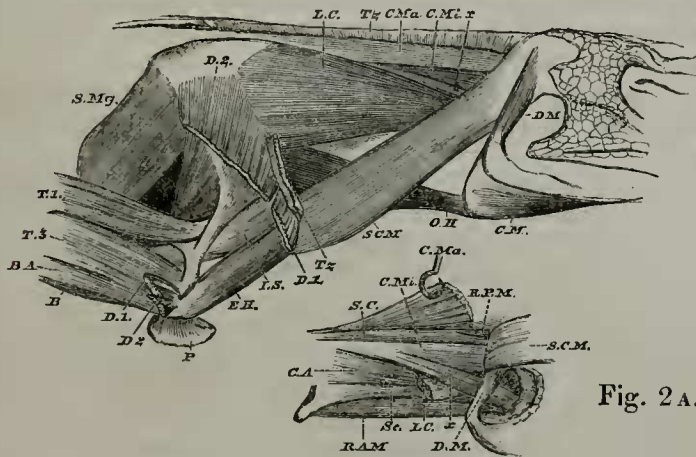


Fig. 2A.

Fig. 2.

Muscles of neck and shoulder, the trapezius and deltoid being cut short.

- B.* Biceps. *B. A.* Brachialis anticus. *C. M.* Cerato-mandibular. *C. Ma.* Complexus major. *C. Mi.* Complexus minor. *D. 1.* First part of deltoid. *D. 2.* Second part of deltoid. *D. M.* Depressor mandibulae. *E. H.* Epicoraco-humeral. *I. S.* Infraspinatus. *L. C.* Levator claviculae. *O. H.* Omo-hyoid. *P.* Pectoralis. *S. C. M.* Sterno-cleido-mastoid. *S. Mg.* Serratus magnus. *T. 1.* External long head of triceps. *T. 3.* External humeral head of triceps. *Tz.* Trapezius. *x.* Fasciculus from complexus minor. The muscle between *D. 2.*, *S. Mg.*, and *T. 1.* is the subscapularis.

Fig. 2A.

Deeper muscles of right side of neck, the levator claviculae being cut short, the sterno-cleido-mastoid cut and reflected forwards, and the complexus major cut and raised.

- C. A.* Cervicalis ascendens. *C. Ma.* Complexus major. *C. Mi.* Complexus minor. *D. M.* Depressor mandibulae. *R. A. M.* Rectus capitis anticus major. *R. P. M.* Rectus capitis posticus major. *Sc.* Scalenus. *S. C. M.* Sterno-cleido-mastoid. *x.* Fasciculus from complexus minor.

second dorsal vertebræ, and from the transverse processes of the last four cervical vertebræ. It is inserted into the supraoccipital and into the parietal process.

*Complexus minor* (figs. 2 & 2A, *C. Mi.*). A muscle placed externally to the last arises from the transverse processes of the last four cervical vertebræ. It is inserted, by strong tendinous fibres, into the end of the parotic process, but gives off from its outer side a fasciculus (figs. 2 & 2A, *x*) which passes to the postero-external end of that depending process of the basioccipital which bounds internally the posterior part of the eustachian aperture.

*Cervicalis ascendens*. This (fig. 2A, *C. A.*), as has been said, is the continuation forwards of the sacro-lumbalis. It is inserted by tendinous fibres into the outer sides of the cervical ribs and into the transverse processes of the four anterior cervical vertebræ (including the atlas), which have no ribs.

*Spinalis colli* (fig. 2A, *S. C.*). The innermost portion of the deep part of the dorsal extensor mass fills the groove between the spinous and articular processes of the cervical vertebræ. It ends at the occiput, where it enters the deep fossa between the supraoccipital and the diverging parietal processes.

*Rectus capitis posticus major*. A more or less distinct muscular fasciculus (fig. 2A, *R. P. M.*) arises from the spinous process of the axis, and is inserted into the supraoccipital.

*Scalenus*. The scalene muscles appear to be represented by a very obscurely separable small muscular mass, which extends from the transverse processes of the first four cervical vertebræ to the anterior margin of the first cervical rib. It lies between the cervicalis ascendens and the rectus capitis anticus major (fig. 2A, *Sc.*).

The *longus colli* arises from the ventral surfaces of the bodies of the atlas and two following cervical vertebræ. It is inserted into the same surfaces of the next four cervical vertebræ and into the last three cervical ribs near their origins.

*Rectus capitis anticus major* (fig. 2A, *R. A. M.*). This muscle arises from the posterior end of the under surface of the basioccipital, and largely from the process bounding internally the posterior end of the eustachian aperture. Passing backwards it is inserted into the bodies of the cervical vertebræ from the fourth to the seventh inclusive, and finally into the anterior margin of the deep surface of the rib of the seventh cervical vertebra.

*Rectus abdominis*. The abdominal muscles are largely developed, both as regards superficial extent and number, as there appear to be no less than three layers of the external oblique muscle. The *rectus* is broad, but rather ill-defined superficially as to its outer margin, which, however, is readily seen on its internal surface. It arises by a strong tendon from the posterior end of the ventral surface of the symphysis ischii (figs. 13 & 14, *R.*). Thence it runs forwards along the middle line of the belly, and is inserted into the posterior margin of the last sternal rib, whence it is continued to the last sternal rib but one, where it is conterminous with the pectoralis major (fig. 6, *R.*), which is apparently its anterior prolongation.

The lateral superficial margins of the muscle are indistinguishably blended with the external oblique, which sends oblique tendinous fibres right across the superficial surface of the rectus.

*External oblique.* This muscle seems to consist of three parts\* :—

(1) The most superficial portion arises by tendinous interdigitations with the dorsal extensor muscles, from the last cervical and all the thoracic ribs. It is a very delicate layer, and ends below by blending with the upper margin of the rectus, with which it becomes inseparably united. It is also inserted (by a tongue of muscular fibres) just above the very strong tendon of insertion of the third portion. It has five tendinous intersections.

(2) The second part arises, beneath the first, by less marked digitations from all the thoracic ribs. Passing downwards and backwards, its most anterior portion is strongly inserted into the fifth thoracic rib; elsewhere it ends in a delicate aponeurosis, which is connected with the sixth thoracic rib, and blends with the inner surface of the first or most superficial layer of the muscle.

(3) The third part of the *external oblique* (fig. 1, *E. O.*, and fig. 13, *Ex. o.*) arises from the posterior surface of the last thoracic rib and from the lumbar fascia. It is inserted, by a very strong tendon, into the spine of the pubis.

This muscle appears to continue backwards the upper, or external, intercostals.

The *internal oblique* is of great extent, lining the whole of the thorax. It arises from the inner surfaces of all the thoracic ribs, beginning by a tendinous aponeurosis which is attached to them along a line nearly corresponding to the outer edge of the dorsal extensor muscular mass. It also takes origin from the lumbar fascia just behind the third part of the external oblique. It is inserted by muscular digitations into the inner surfaces of the sternal ribs and (in the abdomen) into the margin of the rectus.

This muscle is evidently not continuous with the internal (or sternal) *intercostals*, as these are superficial to the fleshy insertions of the internal oblique, the fibres of which, moreover, run more parallel to the sternal ribs themselves than do the fibres of the internal *intercostals*.

*Transversalis.* This muscle is also very extensive, arising by a fascia extending from the pelvis to the last but one cervical rib. Indeed the fascia is continued on into the neck, where it passes beneath the nerves of the brachial plexus, which are external to it, like the abdominal nerves which pass between it and the internal oblique. It is inserted into the border of the *rectus* and the inner sternal part of the thorax.

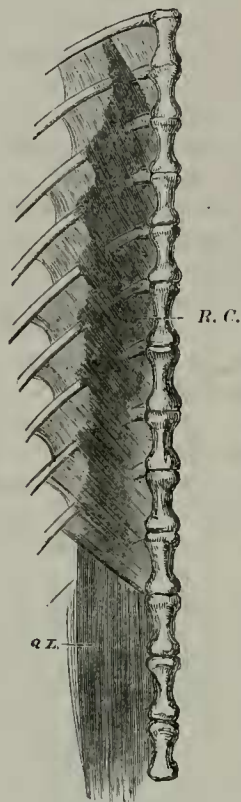
*Internal intercostals.* These extend between the sternal thoracic ribs, reaching vertically to the vertebral ribs, and underlying for some distance the external intercostals.

*External intercostals.* The external ones extend between the cervical ribs, as well as those of the trunk. In the thorax they only

\* Stannius considers that the external oblique and internal oblique each consist of two layers (*loc. cit.* p. 104).

extend down to the junction of the vertebral ribs with the sternal ones.

Fig. 3.



Subvertebral muscles of right side.

*Q. L.* Quadratus lumborum. *R. C.* Retrahentes costarum.

*Retrahentes costarum.* A very remarkable muscular layer\* (fig. 3, *R. C.*), which is tendinous at its insertion and at the posterior part of its origin, but muscular elsewhere. It has a certain resemblance to the diaphragm, as it is internal to all the other body-muscles.

It arises from the sides of the ventral surfaces of the bodies of nine vertebræ, beginning with the first dorsal. The muscular fibres proceed forwards and ventrad, and are inserted into the ribs of the seventh and eighth cervical vertebræ, and into the seven following ribs. The insertion of the aponeurosis is close to the origin of the fascia of the transversalis†.

*Pyramidalis* (fig. 14, *Py.*). This muscle is largely developed, and is placed beneath the rectus. It arises from the ligamentous arch extending back from the spine of the pubis; and its fibres ad-

\* The *m. retrahentes costarum* of Stannius (*loc. cit.* p. 103).

† As Stannius remarks (*loc. cit.* note 4 to p. 103).

vance obliquely forwards towards the middle line of the body, those arising most anteriorly being the longest. The muscle extends forwards more than halfway from the pubis to the sternum.

*Transversus perinei* (fig. 14, *T. Pr.*). This is a thick triangular muscle, arising from the side of the os cloacæ and from the tendinous arch before mentioned passing to the ilium. It fuses more or less completely with the posterior part of the origin of the semimembranosus.

#### CAUDAL MUSCLES.

The essential nature of the *true* caudal muscles is best seen at about the middle of the tail (fig. 4). There the muscular mass of each lateral half of the tail, is easily demonstrated to consist of four longitudinal series of muscular and tendinous cones, the series being placed one above another, and all the cones having their apices directed forwards.

Fig. 4.

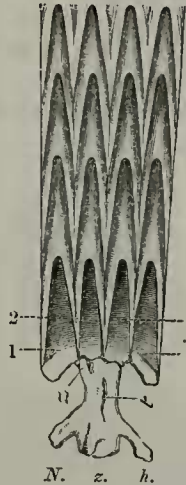


Diagram of caudal muscular cones of the right side of the tail.

1. Dorsal lateral cone. 2. Upper median lateral cone. 3. Lower median lateral cone. 4. Ventral lateral cone. *h.* Inferior spine. *N.* Neural spine. *t.* Transverse process. *z.* Zygapophyses.

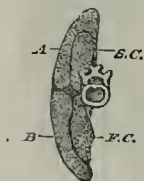
Four such cones appear to spring from each side of each caudal vertebra; but their length generally exceeds that of two such vertebrae. The base of each cone is aponeurotic, with the superficial part glisteningly tendinous. The apex of each cone is muscular. Each cone being hollow, it receives into its cavity the muscular apex of the cone next behind. The repetition of this serial enclosure gives rise to the four longitudinal rows of cones; and as the aponeurosis of each cone is more or less incomplete on its external surface, the tendinous margins of the aperture appear as two glistening lines, which converge anteriorly; moreover, the bases of the cones being on the same vertical line, the appearance of numerous acutely zigzag



lines results, four points being directed forwards and three backwards (fig. 4, 1, 2, 3, 4). Of the four vertically superimposed cones of each vertebra, the topmost one, or the dorsal lateral cone (fig. 4, 1), arises from the neural spine (*N.*) and the zygapophysis (*z.*). The cone next below, or the upper median lateral cone (fig. 4, 2), takes origin also from the zygapophysis; but below from the transverse process or (in more posterior caudal vertebræ) from the strong fascia which takes its place (*t.*). The next cone below, or the lower median lateral cone (fig. 4, 3), arises from the same transverse process or fascia and from the root of the inferior spinous process. The lowest, or ventral lateral cone (fig. 4, 4), springs from (*h*) the inferior spinous process itself.

This arrangement continues forwards to about the fourteenth caudal vertebra. Then the bases of the cones become excluded from the articular processes and from the roots of the hæmal spines by the intrusion and backward prolongation of a *supracaudal* muscular mass coming from the trunk (the *sus-caudien externe* of Meckel, vol. v. p. 284), and by that of the *femoro-caudal* below (fig. 5, *S. C.* and *F. C.*); so that the series of cones, being thus modified, come to form a muscular sheath for these intruding muscles, the sheath being strongly attached still to the ends of the transverse processes and of the neural and hæmal spines.

Fig. 5.



Muscles of right half of a transverse vertical section of the tail at the seventh caudal vertebra, showing the separation of the caudal cones from the vertebra by the intrusion of the supracaudal above and of the femoro-caudal below.

*A.* Superior lateral caudal cones. *B.* Inferior lateral caudal cones.  
*F. C.* Femoro-caudal. *S. C.* Supracaudal.

The two series of median lateral cones more and more approximate as they approach the trunk, and, ultimately coalescing, are inserted strongly into the first caudal transverse process (fig. 15, *x*).

The dorsal lateral cones, much modified, continue on as the *longissimus dorsi*.

The ventral lateral cones terminate mainly by a very strong tendon implanted into the posterior end of the tuberosity of the ischium (close to the origins of the two parts of the semimembranosus), a portion, however, running on into a *sphincter cloacæ*\*.

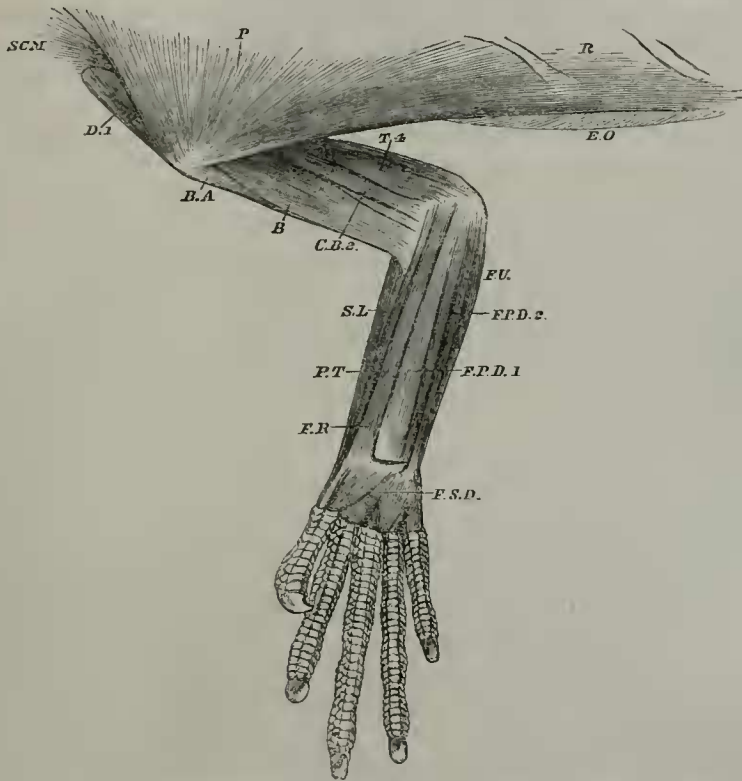
Of the intruding muscular masses the femoro-caudal, inserted into the femur, extends for about one-sixth of the length of the tail, as Meckel says†, or to about the thirteenth caudal vertebra.

\* Meckel, *loc. cit.* p. 285.

† *Loc. cit.* p. 286.

The dorsal mass or *supracaudal* muscle is in part the continuation backwards of the sacro-lumbalis, in part takes fresh origin from the posterior surface of the ilium. It extends backwards also to about the thirteenth caudal vertebra.

Fig. 6.



Superficial muscles of front of thorax, of inside of right arm, and of flexor surface of right forearm.

*B.* Biceps. *B. A.* Brachialis anticus. *C. B. 2.* Second or long part of coracobrachialis. *D. 1.* First part of deltoid. *E. O.* External oblique. *E. U.* Extensor carpi ulnaris. *F. P. D. 1.* First part of flexor profundus digitorum. *F. P. D. 2.* Second part of flexor profundus digitorum. *F. R.* Flexor carpi radialis. *F. S. D.* Flexor sublimis digitorum. *P.* Pectoralis. *P. T.* Pronator teres. *R.* Rectus abdominis. *S. C. M.* Sterno-cleido-mastoid. *S. L.* Supinator longus. *T. 4.* Fourth part of the triceps.

#### MUSCLES OF THE PECTORAL LIMB.

*Pectoralis major* (figs. 1, 2, 6, 8 & 10, *P.*). This muscle is largely developed, and arises from the sternal part of the sixth thoracic rib, and from the sternum and interclavicle, from the posterior end of the former to the anterior extremity of the latter.

From this extensive origin its fibres converge, and are inserted into the most prominent part of the radial tuberosity of the humerus, just opposite the insertion of the deltoid, but separated from the

latter by the summit of the brachialis anticus and by the insertion of the epicoraco-humeral. Externally the pectoralis major is intimately connected with the outermost layers of the external oblique, while posteriorly, as Meckel remarks\*, it is similarly united with the rectus abdominis, of which, indeed, it has every appearance of being the anterior continuation.

*Costo-coracoid* (figs. 7 & 9, *C. C.*). A thin sheet of muscular fibres arises from the anterior margin of the first sternal rib, and is inserted into the deep surface of that strong tendon which is described below as in part the origin of the internal long head of the triceps. This tendon passes from the posterior end of the inner surface of the sternum (close to the hinder end of the edge by which it articulates with the coracoid), upwards to the anterior border of the scapula, between the spinous process projecting from that border and the point of attachment of the clavicle, and dividing the anterior (or lower) part of the subscapularis from its posterior portion.

This muscle answers no doubt to that which, in the *Echidna*†, goes from the first rib to the coracoid; for I have found such a muscle in *Alligator lucius*, and it is noticed by the Rev. Dr. Haughton in the *Crocodile*‡ under the name "*pectoralis secundus*"—a term I would readily adopt, but that I am inclined to think that the muscle may be the homologue of either the pectoralis minor or the subclavius. Stannius§ speaks of it as the sterno-scapular; but this name has been applied to a muscle widely different||.

*Serratus magnus* and *levator anguli scapulae* (figs. 2 & 7, *S. Mg.*). Several small sheets of muscle proceed from certain ribs to the posterior margin and inner surface (towards the superior margin) of the scapula. These may perhaps include, besides the true serratus magnus, not only the *levator anguli scapulae*, but also the *rhomboideus*, though I am inclined to regard the latter muscle as absent in the Iguana, not having succeeded in finding the muscle which Meckel speaks of¶ as having the same disposition in that animal as in the Chameleon, though absent in *Polychrus marmoratus*.

There appear to be four principal portions of this complex muscle:—

(1) The largest and most posterior portion arises from the outer surfaces of the last two cervical ribs (*i. e.* those of the eighth and ninth cervical vertebrae) near their free ends. Each rib gives rise to a distinct muscular layer; and these layers are inserted, in common, into about the upper half of the posterior (or axillary) border of the scapula (fig. 7, *S. Mg.* 1). At the lower end of its insertion it is slightly embraced by fibres of the subscapularis, a few of which arise externally to it.

\* *Loc. cit.* p. 343.

† *Trans. Linn. Soc.* 1866, vol. xxv. p. 382.

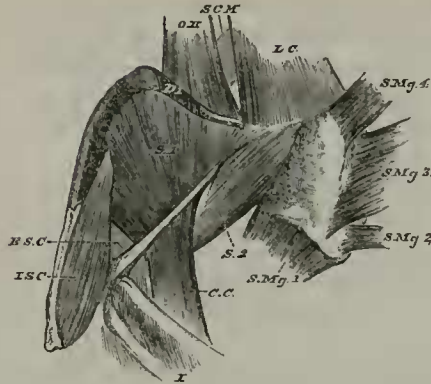
‡ Scientific papers read before the Royal Irish Academy, and published in its 'Proceedings,' 1866, vol. i. p. 702.

§ *Loc. cit.* p. 122.

|| *Proc. Zool. Soc.* 1865, p. 338, and 1866, p. 398 and figs. 2 & 3, *S. s.*

¶ *Loc. cit.* p. 312.

Fig. 7.



Muscles of the inside of the right half of the scapular arch.

*C. C.* Costo-coracoid. *D. 1.* First part of deltoid, curving over anterior (upper) margin of coracoid. *E. S. C.* External sterno-coracoid. *I. S. C.* Internal sterno-coracoid. *I.* Intercostal. *L. C.* Levator claviculæ. *O. H.* Omo-hyoid. *S. 1.* First part of subscapularis. *S. 2.* Second part of subscapularis. *S. C. M.* Sterno-cleido-mastoid. *S. Mg. 1–S. Mg. 4.* Four parts of serratus magnus.

(2) The second and smallest portion (and which some might take to represent the *rhomboideus*) arises from the last but one cervical rib, but considerably higher up than the first portion of the serratus, but considerably higher up than the first portion of the serratus magnus. It is inserted (fig. 7, *S. Mg. 2*) into the inner surface of the posterior (inferior) vertebral angle of the scapula.

(3) The third portion arises from the outside of the ribs of the sixth and seventh cervical vertebræ. It is inserted (fig. 7, *S. Mg. 3*) along the inside of the cartilaginous summit of the scapula, not far from its vertebral margin, and extending along the greater part of the extent of that margin. This portion is double at its origin, each rib giving rise to its own layer of muscle; but the two have a common insertion.

(4) The fourth part of the serratus magnus springs from the outside of the seventh cervical rib, below the origin of the third portion of the serratus. It is inserted (fig. 7, *S. Mg. 4*) into the inner side of the cartilaginous part of the scapula close to the anterior (superior) vertebral angle, between the most anterior parts of the origin of the subscapularis and of the insertion of the third portion of the serratus.

*Deltoid* (figs. 1, 2, 7 & 8, *D. 1* and *D. 2*). This muscle is very large, and, in the specimen examined by me\*, is easily separable into two parts, which, however, have a common insertion:—

(1) The lower portion consists also of two layers, superimposed one on the other,—the superficial layer arising from about the lower (or sternal) half of the posterior part of the deep surface of the clavicle, and from a similar extent of the hinder border of that bone, posterior to the attachments of the trapezius, omo-hyoid, and sterno-

\* This was not the case in Meckel's specimen (*loc. cit.* p. 340).

cleido-mastoid. The deeper layer of the same part of the deltoid springs from the anterior part of about the sternal third of the superficial surface of the clavicle, and just in front of the attachment of the two last-mentioned muscles, which, passing forwards, hide it. It then curves over the anterior margin of the clavicle, and passing backwards, between that bone and the epicoracoid, appears to join the first or more superficial layer.

When the scapular arch is looked at from within, this layer is visible (fig. 7, *D. 1*) immediately above the lower (anterior) portion of the subscapularis, and nearer the observer than the omo-hyoid and sterno-cleido-mastoid muscles.

(2) The upper and larger portion of the deltoid arises from the deep surface and posterior border of the clavicle for rather more than its upper third, and from the outer surface of the scapula for the whole extent between the lower part of the attachment of the levator claviculæ and the hinder (or axillary) margin of the bone. It does not extend upwards to the superior margin of the cartilaginous upper portion of the scapula (fig. 2, *D. 2*),—that part presenting externally a space to which no muscle is attached between this upper or second portion of the deltoid, the serratus magnus, and levator claviculæ.

The two parts of the deltoid are together inserted into the outer side of the radial tuberosity of the humerus, just opposite to the insertion of the pectoralis major, but separated from that muscle by the insertion of the epicoraco-humeral.

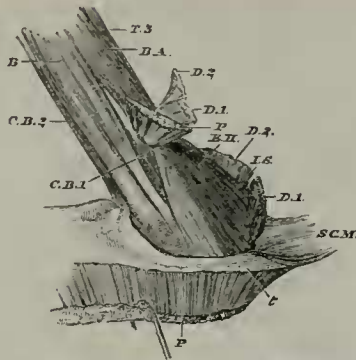
*Infraspinatus* (?). This rather small muscle (fig. 2, *I. S.*) arises from the outer surface of the spinous process of the scapula, and from the membrane intervening between that process and the first or upper spur of the epicoracoid; it takes origin almost down to the margin of the glenoid cavity. Thence it passes downwards in front of the long head of the triceps, and is inserted into the outer side of the humerus just below the head of the bone and between the summits of the external and internal humeral heads of the triceps. Its insertion is mainly superior to that of the latissimus dorsi, though the tendon of the latter slightly overlaps it.

The infraspinatus is as it were strapped down by a strong ligamentous band, which passes from the lower part of the axillary margin of the scapula to the outside of the head of the humerus, underneath the epicoraco-humeral and above the insertion of the deltoid.

The *epicoraco-humeral* is very largely developed, and arises from the two spurs of the epicoracoid and from the intervening membrane which closes the fenestra. It is inserted (figs. 2, 8 & 10, *E. H.*) into the summit of the radial tuberosity between the insertions of the pectoralis major and deltoid. It is covered externally by the lower part of the deltoid and by the pectoralis major; and its inferior margin is much connected with the adjacent part of the coraco-brachialis.

This muscle appears to me to answer to that which I have called by the same name in the *Echidna* (Trans. Linn. Soc. vol. xxv. 1866, p. 383, and pl. 52. fig. 2, *E. H.*).

Fig. 8.



Muscles of inside of right arm, the pectoralis and deltoid being cut short and reflected.

*B.* Biceps. *B. A.* Brachialis anticus. *C. B. 1.* First, or short, part of coraco-brachialis. *C. B. 2.* Second, or long, part of coraco-brachialis. *D. 1.* First part of deltoid. *D. 2.* Second part of deltoid. *E. H.* Epicoraco-humeral. *I. S.* Infraspinatus. *P.* Pectoralis. *S. C. M.* Sterno-cleido-mastoid. *T. 3.* Third, or external humeral, head of triceps. *t.* Tendinous fascia of origin of sterno-cleido-mastoid extending, between epicoraco-humeral and pectoralis, backwards to the true sternum.

*Subscapularis.* This muscle is enormously developed, and is divisible into two parts (fig. 7, *S. 1* and *S. 2*):--

(1) The first portion arises from the whole internal surface of the coracoid and epicoracoid, the spinous process of the scapula, and the membrane of each fenestra. The fibres converge, and towards its insertion this portion fuses with the second part.

(2) The second portion arises from the lower part of the internal surface of the scapula and from the lower half of its posterior, or axillary, margin. It becomes tendinous towards its insertion, and, fusing with the first part, is attached to the ulnar tuberosity of the humerus and to the capsular ligament. This muscle is shown in fig. 2 (though its letter has been accidentally omitted), between *D 2*, *S. Mg.*, *T. 1*, and the band binding down *I. S.*

*Internal sterno-coracoid* (fig. 7, *I. S. C.*). The specimen examined by me had had the whole ventral surface of the body medianly divided from behind forwards, so that I cannot define the inner limit of this muscle. It arises, however, from the deep surface of the sternum, internal to the line of its junction with the coracoid and to the attachments of the ribs, and is inserted, by tendinous fibres, into the deep surface of the coracoid and lower part of the epicoracoid (*i. e.* to the deep surface of its lower spur), where it is contiguous to the inferior margin of the first portion of the subscapularis.

*External sterno-coracoid* (fig. 7, *E. S. C.*). This is a much smaller muscle than the preceding, which overlaps it when the inner surface of the scapular arch is looked at. It arises from the deep margin of that furrow (on the outer edge of the sternum) which receives the coracoid, and is inserted into the coracoid and epicoracoid, passing between those bones and the tendon of the internal sterno-coracoid.

The *sterno-cleido-mastoid* is of large size (figs. 1, 2, 2A, 6 & 8, *S. C. M.*). It arises by muscular fibres from rather more than the lower half of the outer margin of the anterior surface of the clavicle, and by a very strong tendinous fascia (fig. 8, *t.*) from the anterior part of the true sternum. This strong fascia extends forwards (covered by the pectoralis major); and the muscular fibres springing from it arise in a point between the pectoralis major and the lower portion of the deltoid. The muscle passes forwards, overlapping first the omo-hyoid, and afterwards the levator claviculæ. It then becomes intimately united with the outer side of the anterior part of the trapezius, and is inserted into the outer half of the postero-superior margin of the parietal process and into the postero-external end of the parotic process.

*Sterno-hyoid.* This was so much injured in my specimen that I am unable to describe it; according to Cuvier\* and Meckel†, however, it proceeds from the outer part of the sternum to the os hyoides.

The *omo-hyoid* (figs. 2 & 7, *O. II.*) is rather large, and arises from rather more than the upper half of the clavicle, where externally it is adjacent to the trapezius and sterno-cleido-mastoid and internal to the deep layer of the first part of the deltoid. It is mainly inserted into the posterior cornu of the hyoid; but some fibres pass (nearer the middle line of the body) to the body of the os hyoides.

*Levator claviculæ.* This large muscle has a strong tendinous origin from the transverse process of the atlas. Passing backwards it emerges from beneath the sterno-cleido-mastoid (figs. 2 & 7, *L. C.*), and, spreading out, is inserted into the summit (or acromial end) of the clavicle and into the anterior margin of the scapula. About the lower half of its insertion is conterminous, posteriorly, with the origin of the upper (or second) portion of the deltoid; internally this muscle is in close juxtaposition with the second part of the subscapularis and the fourth part of the serratus magnus (fig. 7, *L. C.*).

The *triceps* (figs. 1, 2, 6, 8, 9 & 10) arises by four distinct heads‡, of which two are long, descending from the scapular arch:—

(1) The first part or external long head (which appears to answer to the ordinary long head of this muscle in mammals) arises from the strong, tendinous strap, or ligament before described as passing from the axillary margin of the scapula to the head of the humerus and as binding down the infraspinatus. Thus the head may be said to arise by a bifurcating tendon like that of the rectus femoris of Man (figs. 1, 2 & 9, *T. 1*).

(2) The second part, or internal long head (fig. 9, *T. 2*), takes origin by a long and rather slender tendon, which also bifurcates above,—its lower bifurcation being attached to the postero-internal angle of the deep surface of the coracoid, while its upper bifurcation fuses with that before-described tendinous arch into which the costo-coracoid muscle is inserted.

This second head of the triceps soon joins with the first head, and at its union with the latter receives a small tendinous slip (fig. 9, *t.*)

\* *Loc. cit.* vol. iv. part 1, p. 531.

† *Loc. cit.* vol. viii. p. 135.

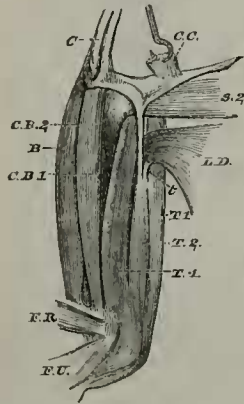
‡ Meckel, *loc. cit.* p. 364.

from the tendon of the latissimus dorsi. Is this head the homologue of the dorso-epitrochlear, which sometimes, as in Hyrax\*, takes origin from the scapular arch, but normally springs from the tendon of the latissimus dorsi?

(3) The third, or external humeral head, arises from the whole outer surface of the humerus below the head of the bone, extending as it does above the insertions of the deltoid and infraspinatus (figs. 1, 2, 8 & 10, *T. 3*).

(4) The last, or internal humeral head (figs. 6, 9 & 10, *T. 4*), similarly arises from the internal surface of the humerus to the head of the bone. At its summit this part of the muscle has contiguous to it, antero-internally, the short part of the coraco-brachialis and the insertion of the subscapularis, while the tendons of the latissimus dorsi and infraspinatus are contiguous to it on its postero-external side (fig. 9).

Fig. 9.



Muscles of inside of right arm, the scapular arch being detached, and the costo-coracoid muscle (*C. C.*) being cut short and reflected.

*B.* Biceps muscle. *C.* Sternal margin of coracoid bone. *C. B. 1.* First, or short, part of coraco-brachialis muscle. *C. B. 2.* Second, or long, part of coraco-brachialis. *C. C.* Costo-coracoid. *F. R.* Flexor carpi radialis. *F. U.* Flexor carpi ulnaris. *L. D.* Latissimus dorsi. *S. 2.* Second part of subscapularis. *T. 1.* First, or external long, head of triceps. *T. 2.* Second, or internal long, head of triceps. *T. 4.* Fourth, or internal humeral, head of triceps. *t.* Tendon from latissimus dorsi to triceps.

All these four portions are united together at above the middle of the arm, and are together inserted into the proximal end of the ulna and into the patella-like sesamoid immediately above it.

*Coraco-brachialis.* This muscle consists of two parts:—

(1.) The first of these, or shorter portion, is a broad muscle, and much resembles the short coraco-brachialis of the *Echidna*†. It arises, by muscular fibres, from the whole outer surface of the coracoid, from the lower spur of the epicoracoid, and from the membrane

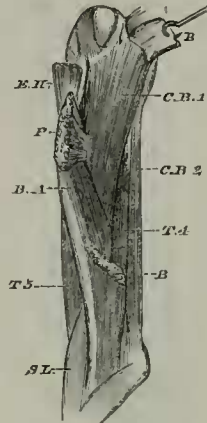
\* Proc. Zool. Soc. 1866, p. 340, fig. 5, *D. c.*

† Trans. Linn. Soc. vol. xxv. p. 385.



intervening between these, and is inserted into the front of the humerus from the head and internal tuberosity to the middle of its shaft. The limit of its insertion begins above at the insertions of the epicoraco-humeral and pectoralis major, and below is continuous with the origin of the brachialis anticus (figs. 8, 9 & 10, *C. B. 1*). From the extent of its insertion this portion appears to me to answer both to the *coraco-brachialis proprius vel medius* and to the *rotator humeri* or *coraco-brachialis superior vel brevis* of Mr. Wood\*.

Fig. 10.



Flexor surface of right upper arm, the biceps and pectoralis major being cut short.

*B.* Biceps. *B. A.* Brachialis anticus. *C. B. 1 & 2.* Coraco-brachialis. *E. H.* Epicoraco-humeral. *P.* Pectoralis major. *S. L.* Supinator longus. *T. 3 & 4.* Triceps.

(2) The second, longer portion (figs. 6, 8, 9 & 10, *C. B. 2*), which seems to answer to the *coraco-brachialis longus* of Mr. Wood†, arises, by muscular fibres, from the posterior end of the sternal border of the coracoid, and is inserted into the internal condyle of the humerus and into the shaft of the bone for a very slight distance above that condyle. There is a glistening tendon on the side next to the bone of the lower half of this portion of the coraco-brachialis.

The *biceps* (figs. 1, 2, 6, 8, 9, 10 & 12, *B.*) has, as in the *Echidna*‡, but a single head§, which takes origin, by a very broad tendon (with an aponeurotic longitudinal interval), from the anterior (not sternal) margin of the coracoid and adjacent part of the epicoracoid, and passes backwards so as to be immediately superficial to the short part of the coraco-brachialis. It soon fuses with the *brachialis anticus*, and is inserted in common with that muscle (by a very strong tendon, which slightly bifurcates below) into the upper parts of both radius and ulna; but the fibres continuous with the *biceps*

\* Journal of Anat. and Phys., Cambridge, 1866, vol. i. pp. 48, 49.

† *Loc. cit.* p. 49.

‡ Trans. Linn. Soc. vol. xxv. p. 385.

§ Unless what I have named *brachialis anticus* be a humeral head of the *biceps*.

appear to go mainly to the ulna. Thus its insertion has much resemblance to that of the same muscle in the *Echidna*.

The *brachialis anticus* (figs. 1, 2, 6, 8 & 10, *B. A.*), which may be, as Meckel appears to think\*, a humeral head of the biceps, springs from the front of the shaft of the humerus, immediately below the insertions of the deltoid, epicoraco-humeral, and pectoralis major. It soon fuses with the biceps, and is inserted in common with it into the upper ends of the flexor surfaces of both radius and ulna. The fibres of this muscle, however, appear to be connected mainly, if not exclusively, with the radius.

*Supinator longus*. This muscle (figs. 1, 6, 10 & 11) is exceedingly large, and, as Meckel observes†, arises by two heads, which do not unite till far down the forearm (fig. 1, *S. L.*). Indeed I find that that head which has the more posterior (lower) origin may be again divisible at and near its origin into two portions, of which the anterior (upper) one is much the smaller; all these parts, however, arise from the external condyle, and have a common insertion into the radial margin of the radius for almost its whole length, and therefore side by side with the pronator teres as far as the latter extends. The head, which has the more posterior (lower) origin, is intimately connected with the radial extensor.

The *extensor carpi radialis*, which appears to answer to both the *longior* and *brevior* of mammals, arises by tendinous fibres from the outer and posterior surface of the external condyle, immediately superficial to the posterior (lower) part of the origin of the supinator longus, with which, for some distance, it is very intimately connected. Passing downwards (fig. 1, *E. R.*) it divides into three parts, which are inserted, each by a tendon, into the proximal ends of the dorsal surfaces of the second, third, and fourth metacarpals.

*Extensor communis digitorum*. As Meckel observes‡, this muscle has, as it were, "*descendu à la main*" (fig. 11, *E. C.*). It is small, arises from the carpus, and is inserted into the bases of the digits. It is much subdivided, there being more or less distinct fleshy bundles for the several digits.

The *extensor carpi ulnaris* (fig. 1, *E. U.*, and fig. 11, *E. C. U.*) is rather indistinct. It arises indeed by tendinous fibres from the posterior surface of the external condyle; but its insertion is into the adjacent border of another muscle, the flexor carpi ulnaris.

*Extensor ossis metacarpi pollicis*. This is a rather thick muscle which arises from the posterior surface of rather less than the distal half of the ulna. It is inserted into the metacarpal of the pollex (fig. 11, *E. M. P.*).

*Pronator teres* (figs. 6 & 12, *P. T.*). The origin of this muscle is by a very strong tendon attached to the summit of the internal condyle. Its fibres spread out, and are inserted into the lower two-thirds of the radial margin of the radius.

The *flexor carpi radialis* (figs. 6, 9, *F. R.*, and fig. 12, *F. C. R.*) arises from the internal condyle immediately below the origin of the

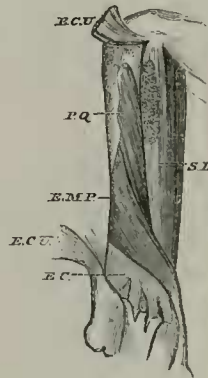
\* *Loc. cit.* p. 362.

† *Loc. cit.* p. 367.

‡ *Loc. cit.* p. 391.

pronator teres. It is inserted into the carpal bone, which articulates with the radius, and also by a small tendon running on (figs. 6 & 12) into the radial side of the metacarpal of the pollex.

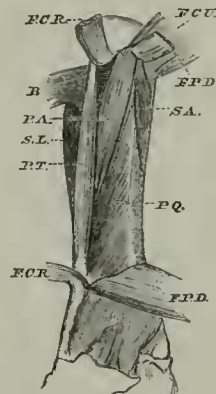
Fig. 11.



Deep muscles of extensor surface of right forearm.

*E. C.* Extensor communis digitorum. *E. C. U.* Origin of extensor carpi ulnaris and common insertion of extensor and flexor carpi ulnaris. *E. M. P.* Extensor ossis metacarpi pollicis. *S. L.* Supinator longus. *P. Q.* Pronator quadratus.

Fig. 12.



Deep muscles of flexor surface of right forearm, the flexor carpi radialis, flexor carpi ulnaris, and flexor profundus digitorum being cut and reflected.

*B.* Biceps. *F. C. R.* Flexor carpi radialis. *F. C. U.* Flexor carpi ulnaris. *F. P. D.* Flexor profundus digitorum. *P. A.* Pronator accessorius. *P. Q.* Pronator quadratus. *P. T.* Pronator teres. *S. A.* Supinator accessorius. *S. L.* Supinator longus.

*Pronator accessorius* (fig. 12, *P. A.*). A muscle I so name provisionally, arises from the anterior surface of the internal condyle, immediately beneath the humeral origin of the flexor profundus digitorum. It is inserted into the radius between the insertion of the pronator teres and that of the pronator quadratus.

*Supinator accessorius* (fig. 12, *S. A.*). Another muscle, which I also provisionally distinguish by a new name, arises from the internal condyle immediately below, but somewhat superficial to the pronator accessorius. It expands as it descends, and is inserted into about the proximal half of the ulnar margin of the ulna.

The *pronator quadratus* (figs. 11 & 12, *P. Q.*) is broadest below, and becomes very narrow towards its upper end. It arises from the flexor surface of the distal half of the ulna and from the whole radial margin of that bone, and it is inserted into the flexor surface of the radius.

*Flexor carpi ulnaris* (figs. 1, 6 & 9, *F. U.*, and fig. 12, *F. C. U.*). This forms a large muscular sheet, which, as usual, has the ulnar nerve passing between its double origin—that from the internal condyle and that from the olecranon. It is inserted into both the pisiforme and fifth metacarpal, as Meckel observes\*. This muscle receives on its postero-external side the insertion of the extensor carpi ulnaris, the two together forming a layer of muscle which wraps round the ulnar side of the forearm.

The *flexor sublimis digitorum* (fig. 6, *F. S. D.*) is a thin muscle entirely confined to the hand†. It arises from the annular ligament, and is inserted into the second phalanges of the digits, being perforated in each case by a tendon of the flexor profundus digitorum.

*Flexor profundus digitorum* (figs. 6 & 12, *F. P. D.*). This is a very thick muscle, and has four, more or less distinct heads of origin.

The first head arises from the internal condyle, immediately beneath the origin of the flexor carpi radialis; it very soon unites with the portion arising from the ulna (fig. 6, *F. P. D.* 1).

The second head also springs from the internal condyle, just below the first head; it also joins the portion arising from the ulna (fig. 6, *F. P. D.* 2).

The third portion takes origin from the greater part of the flexor surface of the ulna.

These three portions unite and give rise to a very strong tendon (in which is a palmar ossicle); and into the deep surface of this tendon are inserted muscular fibres, which spring from the carpus and constitute the fourth head of the muscle.

From the distal margin of this tendon proceed the five perforating tendons, one going to each digit.

*Lumbricales.* I have only observed six lumbrical muscles:—

One going from the ulnar side of the index tendon to the ulnar side of the second digit.

Two from the tendon of the third digit (one on each side), inserted into each side of the third digit.

Two from the tendon of the fourth digit (one on each side), inserted into each side of the fourth digit.

One from the radial side of the fifth digit, inserted into the radial side of the same digit.

*Interossei.* There are dorsal interossei which arise from the carpus, and are inserted one on each side of the proximal phalanx of

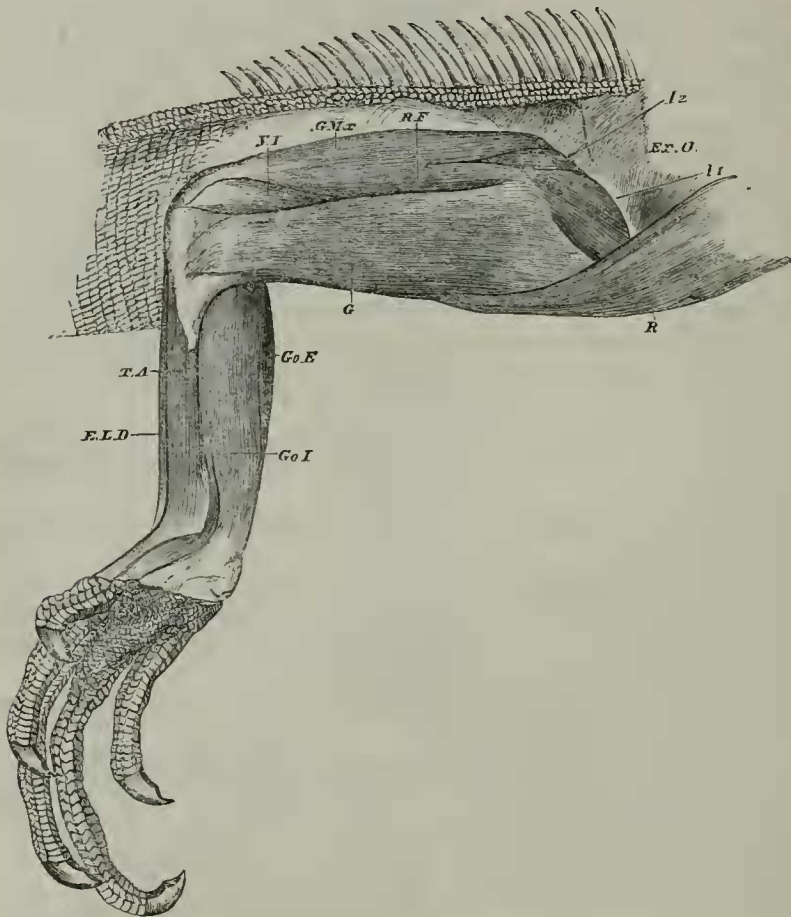
\* *Loc. cit.* p. 383.

† Meckel, *loc. cit.* p. 392.

each digit, except the pollex, which has a large bundle of fibres inserted into the dorsal side of the ulnar border of its *metacarpal*!

Palmar interossei also spring from the carpus, and are inserted one on each side of the proximal phalanx of each of the three middle digits. Another rather large fasciculus is inserted into the radial side of the fifth digit, and, no doubt, represents one or more of the spinal muscles of that digit. Finally, a considerable number of muscular fibres are inserted into the proximal phalanx of the pollex and into the palmar side of the ulnar border of its metacarpal. These fibres, no doubt, represent the *flexor brevis* and *opponens pollicis* of higher animals.

Fig. 13.



Right pelvic limb. Superficial muscles of the anterior surface of the thigh and of the flexor surface of the leg.

*E. L. D.* Extensor longus digitorum. *Ex. O.* External oblique. *G.* Gracilis. *Go. E.* Gastrocnemius externus. *Go. I.* Gastrocnemius internus. *G. M.x.* Gluteus maximus. *I. 1 & 2.* Iliacus and psoas. *R.* Rectus abdominis. *R. F.* Rectus femoris. *T. A.* Tibialis anticus. *V. I.* Vastus internus.

## MUSCLES OF THE PELVIC LIMB.

*Psoas* and *Iliacus*. I am inclined to regard the complex muscular mass which goes from the inside of the pelvis, passing over its brim to the femur, as the homologue of the *psaos* and *iliacus*. I find present four muscular bundles. The first (figs. 13, 14 & 16, I. 1) arises inside the pubis, from a median raphé separating it from its fellow of the opposite side and also takes origin from the most ventral portion of the pubis, overlapping its brim. Its upper (or posterior) margin is conterminous with the inferior (or anterior) margin of the second part of the muscle, and lies superficially to the third part. Passing over the brim of the pelvis, above the spine of the pubis, it is inserted into the tendinous arch going from the front of the acetabulum to the symphysis ischii, and into the upper half of that part of it which is between the acetabulum and the spine of the pubis. It is intimately connected with the second and third parts of this complex muscle and with the tibial adductor.

The second part of the muscle (figs. 13, 14 & 16, I. 2) lies above (*i. e.* nearer the vertebral column than) the first part. It arises also inside the pelvis, from a median raphé which separates it from its fellow of the opposite side. It is inserted in common with the third portion, and is indeed, in part, only with some difficulty separable from the first portion, with the upper (or posterior) margin of which its lower (or anterior) margin is conterminous.

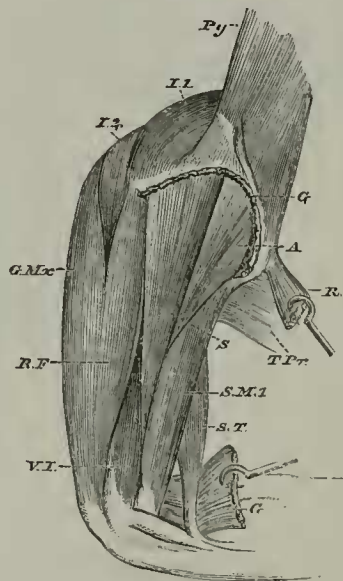
The third portion is a very broad muscular layer, which lies hidden by the first and second portions of the muscle. It arises from the internal surface of the pubis, ischium, and obturator foramen; and the upper (or posterior) part of its origin is easily separable from the more ventral (or anterior) portion. It is inserted into the tibial side of the upper part of the shaft of the femur, internally to the summit of the crureus, just above the insertion of the adductor, and slightly overlapping the tendon of insertion of the femoro-caudal. It is, however, mainly inserted by a strong tendon, which passes across the front of the upper end of the shaft of the femur, beneath the summit of the vastus externus, to the insertion of the gluteus medius, which slightly overlaps it. Thus, the tendinous insertion being on the peroneal side of the bone, while the muscular fibres (inserted with those of the two preceding portions of the *iliacus*) are attached rather to the tibial side, the upper part of the femur comes to be more or less embraced.

The fourth and smallest portion of the complex muscle (fig. 16, I. 4) springs from the surface of that upper (or more posterior) division of the origin of the third part already spoken of (namely that division of the third which arises from the ischium and obturator membrane, and which might be called a fifth portion), and lies nearer the vertebral column than do the other parts. It is inserted in common with the muscular insertion of the third part of the muscle just described; but its fibres are partly continuous with those of the crureus, crossing over the tendon of insertion of the third part of the *psaos* and *iliacus*.

*Quadratus lumborum.* This muscle (fig. 3, *Q. L.*) is very thick at its origin, but thins out anteriorly. It arises from the crest and anterior part of the internal surface of the ilium, and is inserted into the transverse processes of the lumbar ribs, and also of all, or of almost all, the thoracic ones. Besides the short ribs, it is separated, in the lumbar region, from the superimposed dorsal extensor mass by a strong fascia.

*Gracilis.* The muscle which appears to me to represent, possibly, the *gracilis* of mammals is a superficial one on the antero-internal surface of the thigh (figs. 13, 14 & 15, *G.*). It arises from the ischiatic symphysis, and from the long tendinous arch which passes from the front of the acetabulum, round behind the pubic spine, back to the symphysis just mentioned. It is inserted into the outer side of the upper part of the tibia, and at its insertion is intimately united with the semitendinosus. At the lower border of the insertion is a strongish tendon (fig. 14, *G.*), which is common to both muscles, muscular fibres from each being inserted into it.

Fig. 14.



Second layer of muscles of anterior surface of right thigh. The gracilis is cut away short above and reflected below. The rectus abdominis is hooked on one side to show the pyramidalis.

*A.* Adductor magnus. *G.* Gracilis. *G. Mx.* Gluteus maximus. *I. 1 & 2.* Iliacus and psoas. *Py.* Pyramidalis. *R.* Rectus abdominis. *R. F.* Rectus femoris. *S.* Tibial adductor. *S. M.* Semimembranosus. *S. T.* Semitendinosus. *T. Pr.* Transversus perinei. *V. I.* Vastus internus.

The *tibial adductor* is a muscle which arises, beneath the gracilis, from about the upper half of the tendinous arch just mentioned as extending from the front of the acetabulum to the ischiatic sym-

physis (figs. 14, 16, 17 & 18, *S.*). It is slightly connected, at its origin, with the first part of the iliacus, and some fibres spring from the brim of the pelvis just below the tendon of the rectus femoris. Passing downwards between the rectus femoris and the adductor, and passing peronead of the first part of the semimembranosus, it goes very deeply into the popliteal space (between the two heads of the gastrocnemius), and, uniting with the second part of the semimembranosus, is inserted by a tendon into the peroneal side of the head of the tibia above and behind the insertion of the tendon of the biceps. This muscle is easily separable longitudinally into two parts.

*Semimembranosus.* This muscle consists of two portions so distinct in insertion that they may well be considered two separate muscles:—

(1) The first portion (figs. 14, 15, 17 & 18, *S. M.* 1) arises from the tuberosity of the ischium, and from the tendinous arch which passes from the posterior end of the ilium to the spine of the pubis. Its origin is nearly in the same vertical line as, though ventral to, the common origin of the biceps and semitendinosus. Thick and fleshy, it is inserted into the back of the leg, embracing the inner head of the gastrocnemius, some fibres passing beneath the internal lateral ligament, while others extend along the posterior margin of the summit of the tibia.

(2) The second portion (figs. 15, 17 & 18, *S. M.* 2) arises in common with the first portion, and is inserted by a tendon (common to it and to the tibial adductor) into the summit of the peroneal surface of the tibia.

The *semitendinosus* (figs. 14, 17 & 18, *S. T.*) springs in common with the biceps from the strong tendinous arch just mentioned as passing from the posterior end of the ilium to the spine of the pubis, behind and a little above the tuberosity of the ischium. It is inserted by a strong tendon, common to it and to the gracilis, into the inside of the upper part of the tibia, at the lower end of the internal lateral ligament. The insertion is mainly superficial to the last-mentioned ligament; but a few tendinous fibres appear to pass inside it.

*Biceps* (figs. 15, 17 & 18, *B. F.*). This arises, in common with the muscle last described, from the strong ligamentous arch passing from the ilium to the spine of the pubis, and arching over the great femoro-caudal tendon. It is inserted by a slender tendon, which goes very deeply into the popliteal space (between the two heads of the gastrocnemius), and, passing between the tibia and fibula, is inserted into quite the anterior aspect of the outer (peroneal) side of the tibia a little below its upper margin and below and in front of the insertion of the tendon common to the second part of the semimembranosus and the tibial adductor.

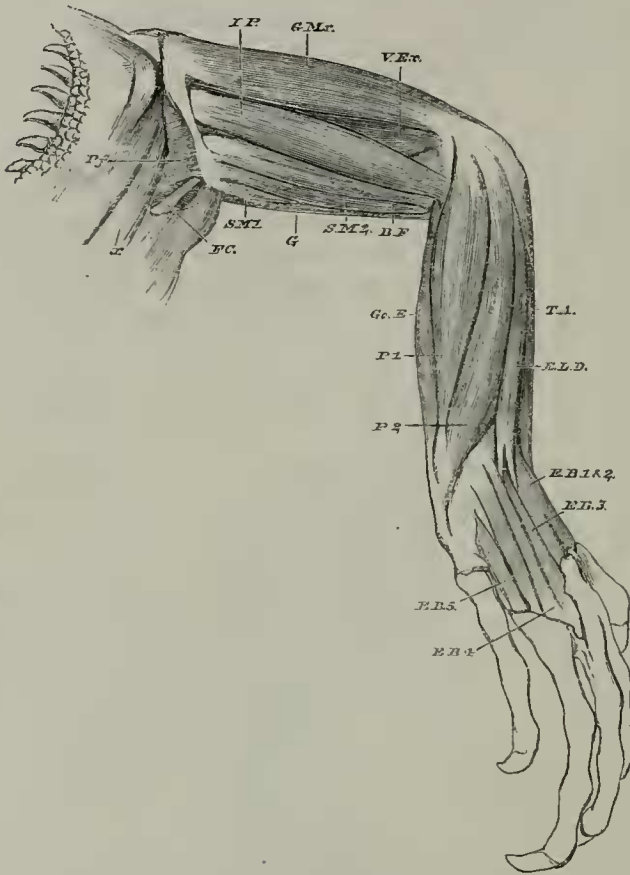
The *biceps* becomes intimately united with the *gastrocnemius*, as it gives off a strong tendon (fig. 18), which runs down just internal to the outer border of the inner head of that muscle.

*Ilio-peroneal* (figs. 15, 16, 17 & 18, *I. P.*). A long and strong muscle, which arises from the posterior part of the outer side of the ilium, covered by the posterior portion of the tendinous origin of the



gluteus maximus, and even a little overlapped by the gluteus medius. It is inserted by a strong tendon (which dips in between the peroneus primus and the outer side of the outer head of the gastrocnemius) into the outer side of the fibula, near its summit\*.

Fig. 15.



Right pelvic limb. Superficial muscles of the posterior surface of the thigh and of the extensor surface of the leg.

*B. F.* Biceps femoris. *E. B. 1-5.* Extensor brevis digitorum. *E. L. D.* Extensor longus digitorum. *F. C.* Femoro-caudal. *G.* Gracilis. *G. Mx.* Gluteus maximus. *Go. E.* Gastrocnemius externus. *I. P.* Ilio-peroneal. *P. 1.* Peroneus primus. *P. 2.* Peroneus secundus. *Pf.* Pyriformis. *S. M. 1 & S. M. 2.* Semimembranosus. *T. A.* Tibialis anticus. *V. Ex.* Vastus externus. *x.* End of the two median series of lateral caudal cones.

*Pectineus?* Three portions of muscle seem more or less to represent the *pectineus* :—

(1) A very small part, which arises from the ligamentous arch before mentioned as passing from the front of the acetabulum, round

\* Meckel, *loc. cit.* p. 428.

by the spine of the pubis, to the ischiatic symphysis. It is inserted into the summit of the trochanter below, and superficial to, the other two portions (fig. 17, *Pc.* 1).

(2) The second part (fig. 17, *Pc.* 2) arises from the down-turned lip of the pubis, from the acetabulum to the symphysis. It is inserted immediately beneath the preceding portion.

(3) The third part (fig. 17, *Pc.* 3) arises from the symphysis pubis, backwards to the middle of the obturator foramen. At the posterior end of its origin the obturator externus is superficial to it and overlaps it. It is inserted into the summit of the trochanter immediately behind the second part.

The *adductor magnus* (figs. 14 & 17, *A.*) is a rather large muscle, which arises, by strong tendinous fibres, from the anterior part of the strong tendinous arch before mentioned which ends in front at the pubic spine. It is inserted into the inner side of the shaft of the femur (for about the second and third fifths of its vertical extent) between the vastus externus and the vastus internus.

*Rectus femoris* (figs. 13, 14, 16 & 17, *R. F.*). This muscle arises, by a very strong and rather broad tendon, from the ventral side of the acetabulum. It blends with the other extensors of the leg and with the aponeurosis of insertion of the gluteus maximus.

*Vastus internus.* A rather small muscle (figs. 14 & 17, *V. I.*) arising from the inside of the shaft of the femur, about as high as the bottom of the uppermost third of the insertion of the adductor; below it blends with the crureus and other extensors of the leg.

*Vastus externus* (fig. 15, *V. Ex.*). This is exceedingly small, and so intimately connected with the crureus as scarcely to admit of definition. It arises from the lowest two-fifths of the postero-external surface of the shaft of the femur, and is inserted with the rest of the extensor mass.

*Crureus* (figs. 16 & 17, *C.*). This muscle is so intimately connected with the last as to be separable from it only with great difficulty. It arises from the front of the femur, its origin extending up near to the head of the bone. It is inserted into the patella along with the rest of the extensor muscular mass. At its summit it is, in part, continuous with the fourth portion of the iliacus.

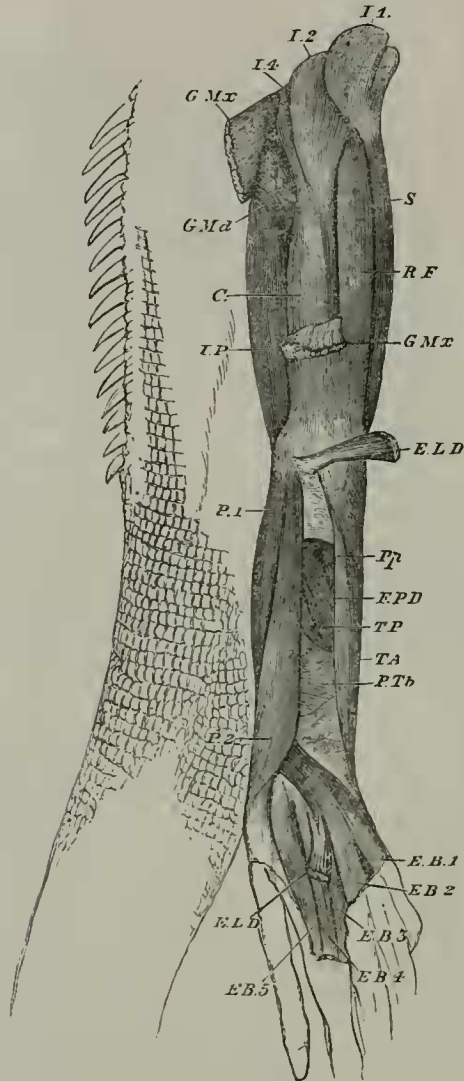
*Gluteus maximus* (?). A muscular layer, which may perhaps represent the gluteus maximus of mammals\*, arises by a very strong tendinous fascia from the outer side and upper margin of the ilium. It covers the antero-external side of the thigh, becomes intimately united with the rectus femoris, and is inserted by aponeurosis into the outer surface of the vastus externus (figs. 13, 14, 15 & 16, *G. Mx.*).

The *gluteus medius* arises from the outer surface of the ilium, between the origins of the gluteus maximus and ilio-peroneal. It is a small muscle, and is inserted into the outer side of the upper part

\* I am very doubtful as to whether this muscle and the next are really *glutei*; but the condition of these muscles in *Echidna* inclines me to name them so, provisionally at least (see Trans. Linn. Soc. vol. xxv. 1866, p. 391, and pl. 53. fig. 2. *G. mx.* and *G. md.*).

of the shaft of the femur behind and external to the summit of the origin of the vastus externus. The upper part of its insertion is into the lower portion of the trochanteric fossa (fig. 16, *G. Md.*).

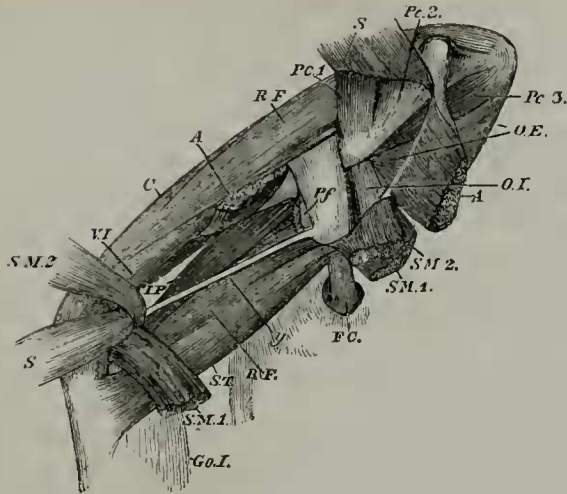
Fig. 16.



Deeper muscles of extensor surface of right pelvic limb. The gluteus maximus and the extensor longus digitorum are each cut short and reflected at both ends.

*C.* Crureus. *E. B.* 1-5. Extensor brevis digitorum. *E. L. D.* Extensor longus digitorum. *F. P. D.* Flexor longus digitorum. *G. Md.* Gluteus medius. *G. Mx.* Gluteus maximus. *I.* 1-4. Iliacus and psoas. *I. P.* Ilio-peroneal. *P.* 1. Peroneus primus. *P.* 2. Peroneus secundus. *Pp.* Popliteus. *P. Tb.* Peroneo-tibial. *R. F.* Rectus femoris. *S.* Tibial adductor. *T. A.* Tibialis anticus. *T. P.* Tibialis posticus.

Fig. 17.



Deepest muscles of right thigh; ventral aspect. The gracilis is entirely removed. The tibial adductor, the semimembranosus, and the adductor magnus are cut short and reflected.

A. Adductor magnus. B.F. Biceps femoris. C. Crunceus. F.C. Femoro-caudal. Go. 1. Gastrocnemius internus. I.P. Ilio-peroneal. O.E. Obturator externus. O.I. Obturator internus. Pc. 1-3. Pectineus. Pf. Pyriformis. R.F. Rectus femoris. S. Tibial adductor. S.M. Semimembranosus. S.T. Semitendinosus. V.I. Vastus internus. *y.* Tendon of insertion of femoro-caudal given off from the larger tendon and going to the popliteal space.

*Obturator externus*\*. This is very fleshy, and arises from the ischium and the outside of the obturator membrane (fig. 17, *O.E.*). It is inserted into the trochanteric fossa immediately above the summits of the insertions of the gluteus medius and pyriformis.

The *obturator internus*† (fig. 17, *O.I.*) arises from the posterior part of the deep surface of the ischium. Curving round the outer margin of that bone (between the acetabulum and the tuberosity), it is inserted, by an *exceedingly* strong tendon, into a pit on the outer side of the articular head of the femur.

*Pyriformis* (figs. 15 & 17, *Pf.*). This muscle‡ arises from the under surfaces of the first four caudal transverse processes, between the large femoro-caudal muscle on the inside and the conjoined insertions of the two median series of lateral caudal cones on the outside. It is inserted into the strong tendinous arch passing from the ilium to the pubis and enclosing the tendon of the femoro-caudal muscle. Thence taking fresh origin, and accompanied by an anterior fasciculus coming direct from the caudal vertebræ, it is finally

\* This appears to answer to the *m. quadratus femoris* of Stannius (p. 134. no. 10).

† The *obturator internus* of Stannius (*loc. cit.* p. 134. no. 5) is a part of my *iliacus*.

‡ It is the *m. subcaudalis* of Stannius (*loc. cit.* p. 133. no. 4).

attached to the base of the back of the trochanter, immediately next to the insertion of the gluteus medius on the one hand and of the femoro-caudal on the other.

*Femoro-caudal* (figs. 15 & 17, *F. C.*)\*. This exceedingly large muscle arises from the infero-lateral aspect of the caudal vertebrae, where it separates from the vertebral column by its backward intrusion (fig. 5, *F. C.*), the contiguous parts of the ventral, and infero-lateral series of caudal muscular cones. It is inserted, by a very large and strong tendon, into the base of the trochanter on its extensor aspect and above the insertion of the adductor. A little before its insertion this large tendon gives off, nearly at right angles, a long delicate one, which, passing down the thigh into the popliteal space (figs. 17 & 18 *y*), is inserted into the interarticular cartilage between the femur and the tibia, as Stannius has stated†.

The *tibialis anticus* (figs. 13, 16 & 18, *T. A.*) arises from the front of the tibia, the part above the middle of the bone springing mainly from its peroneal aspect, and the part below the middle from its inner aspect. It ends in a single tendon, which is inserted into the tibial side of the distal end of the metatarsal of the hallux.

*Extensor longus digitorum.* This muscle arises, by a strong tendon (figs. 13, 15 & 16, *E. L. D.*), from the anterior surface of the external condyle of the femur. It continues fleshy down to the metatarsals, when it suddenly narrows and gives off two small tendons, which pass, one on each side of the middle metatarsal bone, near its proximal end. Of these two tendons, the peroneal one curves round tibial, and is inserted into nearly the middle of the plantar surface of the third metatarsal. The other one is similarly implanted into the second metatarsal.

*Extensor brevis digitorum.* This muscle may be said to consist of five portions:—

(1) The first part (figs. 15 & 16, *E. B.* 1) is an oblique slip, proceeding forwards and inwards, which arises from the peroneal aspect of the lower end of the fibula, and is inserted into the dorsum of the hallux.

(2) The second part (figs. 15 & 16, *E. B.* 2) is similar in size and direction. It arises from the fibula, below the last, and is similarly inserted into the index digit.

(3) The third portion (figs. 15 & 16, *E. B.* 3) arises, by a strong though small tendon, from a pit in the middle of the anterior surface of the astragalus. Passing between the two tendons of the extensor longus digitorum, it is inserted into the dorsum of the third digit.

(4) The fourth part (figs. 15 & 16, *E. B.* 4) arises in common with the preceding, but does not pass between the tendons of the extensor longus digitorum. It is inserted into the dorsum of the fourth digit.

(5) The fifth and last part arises, by a strong tendon, from the bottom of the anterior face of the astragalus (figs. 15 & 16, *E. B.* 5). It is also inserted into the dorsum of the fourth digit.

\* This is the "*sous-caudien profond*" of Meckel (*loc. cit.* p. 285).

† *Loc. cit.* p. 133. no. 3.

*Peroneus primus.* This muscle (figs. 15, 16 & 18, *P. 1*) arises, by a strong tendon, from the summit of the outer side of the external condyle of the femur. Passing downwards, it becomes tendinous just below the outer malleolus, and ends in a tendon which is inserted into the peroneal border of the fifth metatarsal bone, a little above its middle. Behind the ankle its tendon expands into a broad, strong, ligamentous fascia, which binds down the flexor muscles, being attached internally to the internal margin of the hinder surface of the astragalus.

*Peroneus secundus.* A muscle, somewhat larger than the preceding (figs. 15 & 16, *P. 2*), arises from the antero-external surface of the fibula for almost its entire length. It is inserted close above the insertion of the preceding muscle.

*Gastrocnemius.* Two distinct muscles compose the gastrocnemius:—

(1) The first of these (figs. 13, 17 & 18, *G. I.*) arises from the internal condyle of the femur, where it is closely connected with the insertion of the first part of the semimembranosus, which embraces it. It is also attached to the tibial margin of the tibia, close to the insertion of the semitendinosus. Passing downwards, it soon receives a strong tendon from the biceps, which tendon runs down just internal to its outer border. At the ankle it becomes aponeurotic, and constitutes the most superficial and external part of the plantar fascia.

(2) The second head (figs. 13, 15 & 18, *G. E.*) arises from the femur, immediately above the external condyle. Below it becomes a large muscle, considerably greater than the inner head of the gastrocnemius, which latter passes down superficially to this second portion. Becoming aponeurotic at the ankle, it contributes to form the superficial plantar fascia, especially that part which underlies the three peroneal metatarsals, its fibres, indeed, appearing to form as it were perforated tendons to the third and fourth digits.

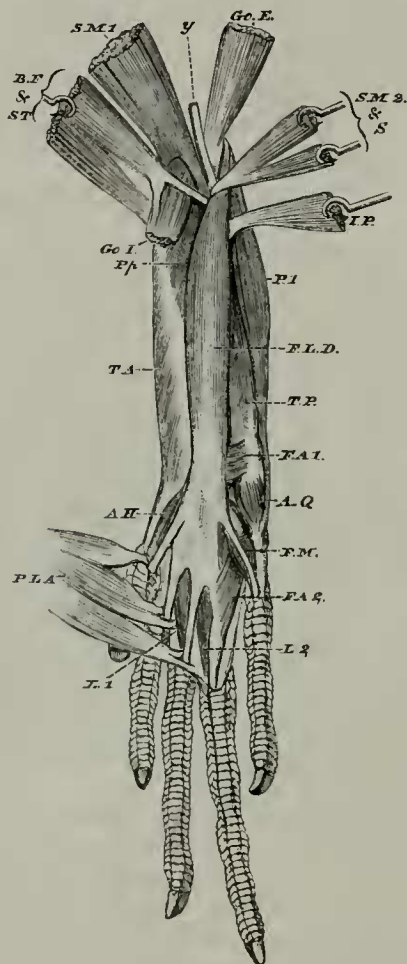
*Plantaris.* This muscle is at its origin so intimately connected with the outer head of the gastrocnemius that it is with some hesitation that I describe it by a distinct name. About the middle of the leg it separates somewhat from the gastrocnemius externus, and thence widens to the ankle, where it receives a reinforcement of a few muscular fibres from the fifth metatarsal bone, in the distal end of the outer surface of which is implanted a tendon which passes along the peroneal edge of the muscle. In the sole this muscle appears as three fleshy bellies (fig. 18, *P.L.A.*), which form the perforated tendons of the second and third digits, and perhaps of the hallux also.

The *popliteus* arises from the tibial aspect of the head of the fibula, and is inserted into the posterior surface and tibial margin of almost the upper half of the tibia (figs. 16 & 18, *Pp.*).

*Flexor longus digitorum* (fig. 16, *F. P. D.*, and fig. 18, *F. L. D.*). This rather large muscle arises (1) partly, in common with the last, from immediately above the external condyle of the femur, (2) from the upper third of the posterior surface (or margin) of the fibula, and (3) from almost the upper half of the tibial side of the fibula,

where it is closely connected above with the peroneal side of the popliteus. The second and third portions arise side by side and are closely connected together. Beneath the astragalus this muscle ends in a wide tendon, which divides into five narrow ones, one of these going to the last phalanx of each digit.

Fig. 18.



Flexor surface of right leg; the two heads of the gastrocnemius being cut off short above, and the plantaris reflected below. The semimembranosus, the biceps and semitendinosus, the ilio-peroneal and the tibial adductor are cut and variously reflected.

*A. H.* Abductor hallucis. *A. Q.* Abductor ossis metatarsi quinti. *B. F.* Biceps femoris. *F. A. 1* & *F. A. 2.* Flexor accessorius. *F. L. D.* Flexor longus digitorum. *F. M.* Flexor minimi digiti. *Go. E.* Gastrocnemius externus. *Go. I.* Gastrocnemius internus. *I. P.* Ilio-peroneal. *L. 1.* & *L. 2.* Lumbricales. *P. 1.* Peroneus primus. *P. L. A.* Plantaris. *Pp.* Popliteus. *S.* Tibial adductor. *S. M. 1* & *S. M. 2.* Semimembranosus. *S. T.* Semitendinosus. *T. A.* Tibialis anticus. *T. P.* Tibialis posticus. *y.* Tendon of insertion of femoro-caudal.

The *tibialis posticus* is very narrow above and very broad below. It arises from the lower half of the posterior surface of the fibula, and its fibres pass downwards and tibial. It ends inferiorly in a broad expanded tendon, which is inserted into the posterior process and whole posterior border of that tarsal bone which fits into the concavity on the under surface of the astragalus (figs. 16 & 18, *T. P.*).

*Peroneo-tibial.* A remarkable muscle connects together rather more than the lowest two-fifths of the tibia and fibula. Its fibres pass from the posterior surface and tibial border of the last-named bone to the peroneal margin, and to a very little of the anterior margin of the tibia (fig. 16, *P. Tb.*). This muscle is unlike any with which I am acquainted, unless it be the very similar one found in the leg of the Wombat.

*Flexor accessorius.* Two small muscular bands, which may perhaps be so named, are thus conditioned:—

(1) The first springs from the plantar aspect of the os calcis, and is inserted into the peroneal side of the tendon of the flexor profundus digitorum before its division.

(2) The second part from the tibial aspect of the ridge on the plantar surface of the fifth metatarsal, and is inserted into the tendons of the second, third, and fourth digits (fig. 18, *F. A. 1* and *F. A. 2*).

*Lumbricales.* I have only detected two muscles which appear thoroughly to answer to mammalian lumbricales.

These arise from the plantar surfaces and tibial sides of the perforating tendon of the third and fourth digits, and go respectively to the tibial sides of the same digits (fig. 18, *L. 1* and *L. 2*).

Three other narrow flat muscular bands go from the deep surfaces of the perforating tendons of the third, fourth, and fifth digits to the plantar surfaces of the proximal phalanges of the same digits.

*Abductor hallucis* (fig. 18, *A. H.*). This is a flat muscular band, which arises from the plantar surface of the naviculare, very near to the proximal end of the first metatarsal, and is inserted into the proximal phalanx of the hallux.

The *abductor ossis metatarsi quinti* (fig. 18, *A. Q.*) is a similar flat muscular band arising from the distal end of the os calcis, and inserted into the peroneal border of the distal end of a groove on the deep surface of the fifth metatarsal bone. Next the surface of this groove is a strong tendon.

*Flexor minimi digiti* (fig. 18, *F. M.*). This small muscle arises from the tibial aspect of the ridge on the plantar surface of the fifth metatarsal, and is inserted into the proximal phalanx of the fifth digit.

*Interossei.* There are dorsal and plantar interossei in the pes very similar to the corresponding muscular fasciculi of the manus; but besides these there is a superficial layer of plantar muscular fibres. This layer takes origin from the tibial side of the cuboid and fifth metatarsal, and is covered superficially by the second part of the flexor accessorius. Spreading out in a fan-like manner, it is inserted into the three middle digits.